

The Influence of Surgeon's Hand Dominance on Surgically Induced Astigmatism (SIA) in Phacoemulsification



Zia-ul-Mazhry¹, Laiba Asif², Muhammad Abdullah Mazhry³
Faiza Hassan⁴, Muhammad Saeed⁵
^{1,2,3}Acuity Eye Center, Lahore ^{4,5}Superior University, Lahore

ABSTRACT

Purpose: To compare the influence of surgeon hand dominance on surgically induced astigmatism in Phacoemulsification.

Study Design: Quasi experimental study.

Place and Duration: Acuity Eye Center, Lahore, from 2023 to 2024.

Methods: Surgically induced astigmatism (SIA) of 200 patients who underwent phacoemulsification by a single experienced surgeon with temporal clear corneal incision was analysed. The surgeon performed phacoemulsification holding the phaco handpiece in the right dominant hand when operating the right eye and the left non-dominant hand when operating the left eye. The patients keratometric (K) values were taken with Nidek auto-refractometer (ARK-510A) 1 day before surgery (Baseline) and 6 weeks post-operatively. The pre-operative and 6 weeks post-operative K values were entered into the spreadsheet. SIA was calculated, analysed and plotted by ASCRS (American Society of Cataract and Refractive surgery) SIA Calculator (V100 Tool). Comparison of SIA between dominant and non-dominant hand phacoemulsification was calculated through SPSS (Version 26).

Results: All the participants were between 30 to 80 years of age. Double angle plot for SIA using ASCRS V100 tool revealed significant insights into the astigmatic changes post-surgery in both the right and left eyes. The centroid values, indicative of the mean astigmatic change, were $0.49 \pm 0.26D$ and $0.55 \pm 0.31D$, respectively. The comparison between both left and right phacoemulsification showed that the difference was non-significant between dominant and non-dominant hand ($P=0.251$).

Conclusion: Despite the challenges of adapting surgical technique to accommodate hand dominance, our findings indicate a non-significant difference in postoperative SIA outcomes.

Key Words: Surgically Induced Astigmatism, Phacoemulsification, Cataract.

How to Cite this Article: Mazhry ZU, Asif L, Abdullah M, Hassan F, Saeed M. The Influence of Surgeon's Hand Dominance on Surgically Induced Astigmatism (SIA) in Phacoemulsification. 2025;41(1):74-79.

Doi: 10.36351/pjo.v41i1.1909

Correspondence: Zia-ul-Mazhry
Acuity Eye Center, Lahore
Email: mazhry@hotmail.com

Received: July 29, 2024
Revised: November 30, 2024
Accepted: December 25, 2024

INTRODUCTION

The hands of a surgeon perform a major role in precision and accuracy of the challenging ophthalmic

surgery, which not only determines the outcome of the procedure but also its subtle aftereffects on the visual acuity of the patient. The exciting issue of surgeon hand dominance stands out among the many variables affecting surgical results as a crucial yet frequently disregarded component. Under the domain of Phacoemulsification Surgery, where each incision shapes the corneal contours, the interaction between the dominant and non-dominant hands of the surgeon reveals a complex story of SIA.¹

The term “surgically induced astigmatism” (SIA)

describes how a corneal incision causes a flattening effect along a particular axis that affects the refractive outcomes of cataract surgery. Preoperative astigmatism, the location and size of the incision, the thickness and structure of the cornea, and the wound healing following surgery are some of the variables that can impact SIA.² Reducing surgically induced astigmatism continues to be a top goal for maximizing visual results of cataract surgery. This goal can be achieved only if the operating surgeon knows astigmatism induced by his own incision technique. Surgeons can optimize surgical techniques to maximize visual acuity and patient satisfaction by knowing the multifactorial nature of SIA and its implications for refractive outcomes. The ophthalmic community continues to discuss and be interested in the impact of surgeon hand dominance, even though SIA is influenced by several factors, including incision size, location, and technique.³

The dominance of a surgeon's hand is associated with the location of the incision, as a surgeon accustomed to using their right hand will naturally find it easier to perform surgery on the right eye while positioned at the head end of the patient. However, when operating on the left eye, they would need to either alter their position or switch hands. Eye surgeons often opt for an alternative approach, which involves relocating the incision site to a superior or superonasal position.⁴ However, this adjustment presents its own set of challenges. Particularly in individuals with deep-set oriental eyes, the brow anatomy may obstruct the smooth execution of phacoemulsification, potentially resulting in wound distortion. Such positional adjustments may not be ideal, and switching hands could prove to be a formidable challenge for a surgeon unaccustomed to using their non-dominant hand.

There are practical implications for clinical practice behind investigating the effect of surgeon hand dominance on SIA beyond theoretical assumptions. For patients undergoing bilateral phacoemulsification surgery, operating with the non-dominant hand in the left eye may improve refractive predictability and modernizes surgical practices if it gives rise to comparable outcomes with surgeries performed by the dominant hand. Furthermore, the comparative research may provide valuable insights that can enhance surgical training programmes, hence promoting the development of abilities and broadening the scope of practice for ophthalmic surgeons. Small

variations in incision width, depth, and position are critical factors in determining surgical results in the complex choreography of ophthalmic surgery.⁵ Of these factors, the optimal effect on astigmatism correction frequently favours precisely placing incisions along the 180-degree meridian.⁶ Adapting a surgical technique to ensure accurate incision placement while accommodating hand dominance is a crucial problem for surgeons, especially when doing procedures on both eyes. This is particularly clear in the case of temporal incisions, when the location of the surgeon in relation to the patient's head is critical. For a right-handed surgeon, achieving the optimal temporal incision on the left eye when positioned at the patient's head end can be difficult and may impair surgical precision for a surgeon who is used to working with their dominant hand.⁷

Surgeons who are adept at using their non-dominant hand, however, can benefit from their increased ease of positioning for the best temporal incision location. Surgeons who position themselves at the head end are better able to perform precise incisions with less disruption to their posture during surgery. This benefit is especially noticeable when aiming for astigmatic neutrality since the temporal location provides more control over the structure of the cornea and the results of refractive outcomes.⁸

This study will help to compare the influence of surgeon hand dominance on SIA in Phacoemulsification with 2.75mm incision, in which the surgeon used the right dominant hand to operate the right eye and left non-dominant hand to operate left eye.

METHODS

A quasi-experimental study was conducted to investigate SIA in 200 patients who underwent phacoemulsification for cataracts. Sample size was calculated through G*Power. The surgeries were performed by a single experienced surgeon utilizing a temporal clear corneal incision. A standardized surgical approach was used across all cases. Pre-operative keratometric (K) values were measured using the Nidek auto-refractometer (ARK-510A) one day before surgery (baseline), with post-operative K values assessed six weeks postoperatively to evaluate changes in corneal astigmatism. SIA was calculated and analysed utilizing the ASCRS SIA Calculator based on the pre-operative and post-

operative K values. Statistical analysis for comparing SIA between surgeries performed with dominant and non-dominant hands was conducted using the Statistical Package for the Social Sciences (SPSS) (Version 26), employing descriptive and inferential statistical methods with a significance threshold set at $p < 0.05$. Patient confidentiality was maintained, and data anonymization was ensured throughout the study.

RESULTS

The study population comprised of 200 patients undergoing phacoemulsification with a balanced gender distribution (Table 1). Most patients fell within the age range of 51-60 and 61-70 years, comprising 36.5% and 38% of the total sample, respectively. This indicates that a significant proportion of patients undergoing cataract surgery were in their fifth and sixth decades of life. Double angle plot for corneal SIA was provided by the ASCRSV100 tool (Figure 1).

This plot of the corneal SIA for OD and OS shows centroid values along with standard deviations, and 95% confidence ellipses of the data set and of the centroid values. Each ring showed a difference of 0.50D.

Table 1:

	Frequency	Percentage
Age of Participants (n=200)		
30-40	4	2%
41-50	3	1.5%
51-60	73	36.5%
61-70	76	38%
71-80	44	22%
Total	200	100%
Gender of Participants (n=200)		
Male	98	49%
Female	102	51%
Total	200	100

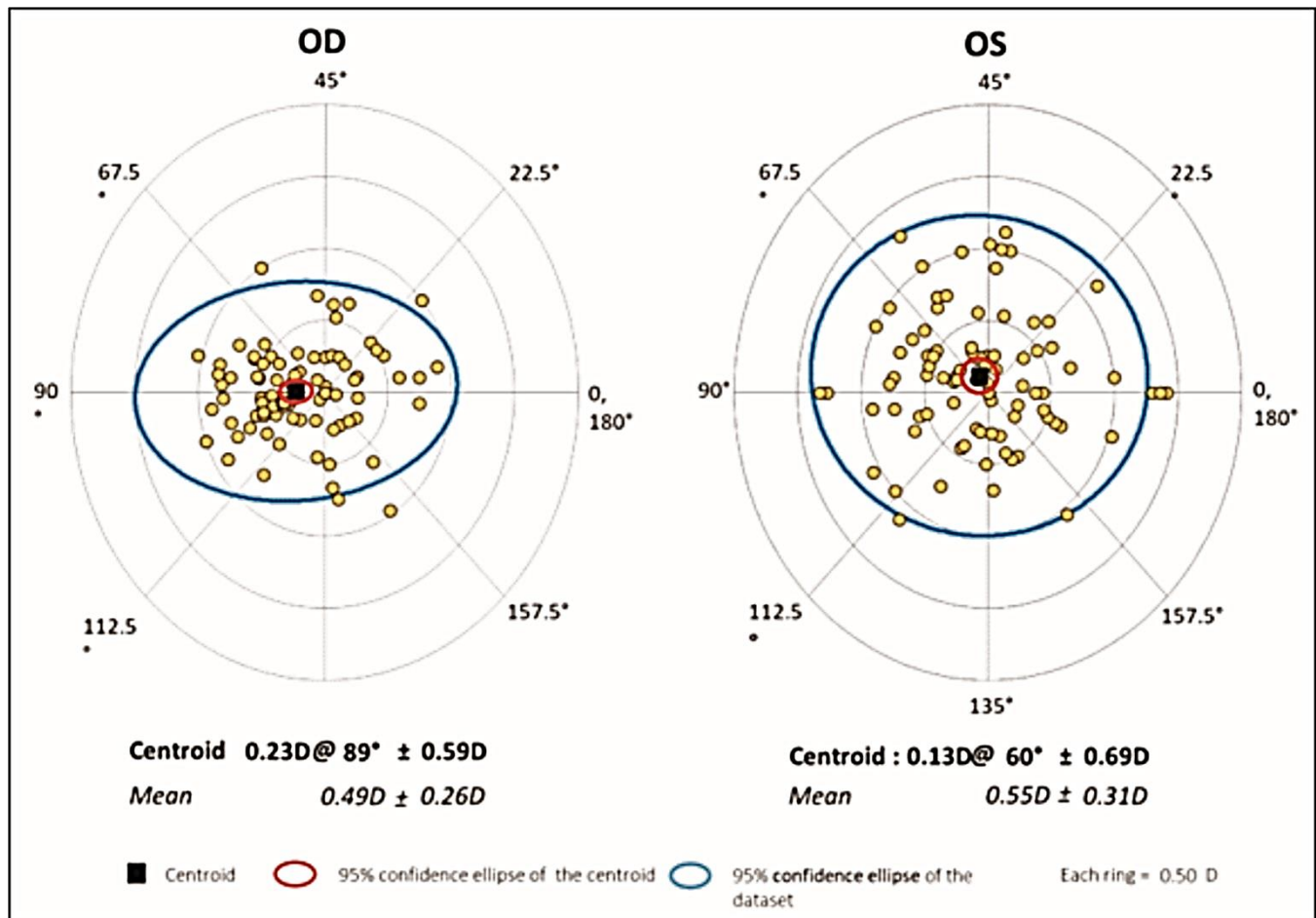


Figure 1: Double Angle Plot for Surgically Induced Astigmatism (SIA) using ASCRS V100 Tool.

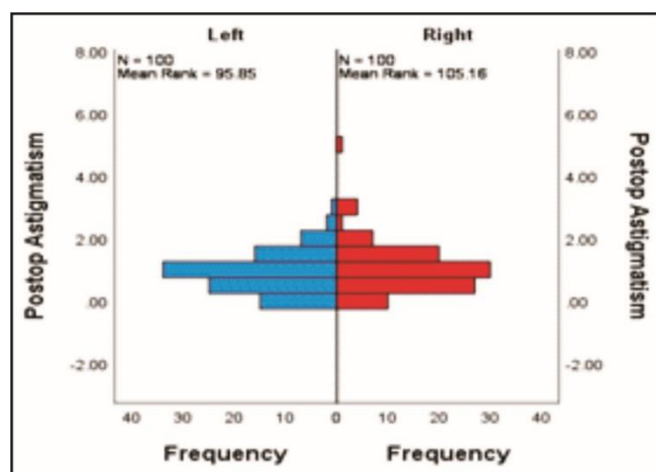


Figure 2: Comparison of postoperative astigmatism in OD and OS.

The analysis of corneal SIA using the ASCRS tool revealed significant insights into the astigmatic changes post-surgery in both the OD and OS. Double-angle plots provided a visual representation of the astigmatic changes, demonstrating the distribution and magnitude of induced astigmatism across different meridians. The centroid values, indicative of the mean astigmatic change, were $0.49 \pm 0.26D$ for OD and $0.55 \pm 0.31D$ for OS, respectively. These metrics offer a precise quantification of the central tendency and variability of the induced astigmatism. Furthermore, the 95% confidence ellipses depicted the dispersion of data points and centroid values with a high degree of certainty. Overall, these results elucidate the corneal astigmatic changes following surgery, providing valuable information for optimizing surgical outcomes and managing postoperative astigmatism.

The evaluation of SIA in the post-operative period between the two eyes revealed no significant disparity as shown in Figure 2 (p-value of 0.251).

DISCUSSION

A considerable learning curve and a high degree of hand coordination are required for cataract surgery. To fill the gap, this study assesses the astigmatism-related refractive results of phacoemulsification carried out by a single, skilled surgeon. The astigmatism that was surgically produced in the OS and OD eyes during phacoemulsification using the surgeon's dominant and non-dominant hands was comparable in our study. This result might come as a surprise at first, but it was probably affected by the surgeon's vast expertise, as the author has been using the right hand for OD and

left hand for OS for about 15 years.

Previous studies while performing phacoemulsification showed an average SIA of 0.60D by Vyas et al.⁹ 0.87D by Hazra S et al.,¹⁰ 1.23D by Reddy Bet al.¹¹ and 0.77D by George R et al.¹² In our study, the SIA was $0.49 \pm 0.26D$ in the right eye and $0.55 \pm 0.31D$ in the left eye, aligning with the average SIA reported internationally for 2.75–2.8 mm incisions. The use of the temporal approach for both OD and OS, combined with the surgeon's expertise, likely contributed to minimizing SIA in our cases. Additionally, literature supports that temporally placed corneal incisions are more effective in reducing SIA compared to superiorly placed incisions.¹³

Using the non-dominant hand for phacoemulsification can be akin to relearning the technique, requiring heightened focus and precision from the surgeon. Additionally, performing phacoemulsification with the non-dominant hand allows the dominant hand to be utilized more effectively for handling other critical instruments, potentially reducing intraoperative complications.

Prior research by Chung et al. found no statistically significant difference in surgical success between young ophthalmologists performing procedures with their dominant versus non-dominant hands.¹⁴ Similarly, Gonzalez et al. reported improved non-dominant hand skills following targeted training.¹⁵ In contrast, another study found that surgeries performed with the non-dominant hand were less reliable, less effective, and required more time.¹⁶ There was no significant difference in the overall refractive outcomes and intraoperative complications between dominant and non-dominant hand surgeries.

Sharma et al. investigated the effects of surgical techniques performed with the right and left hands on endothelial cell changes and refractive outcomes, depending on whether the surgeon was positioned at the head or the temporal side of the patient.¹⁷ However, they did not assess complications. With respect to SIA, endothelial cell loss, and postoperative keratometric astigmatism, the authors found no statistically significant difference between the groups. Another study published in the literature using real-world data found no discernible difference between dominant and non-dominant hand cataract surgery in terms of the quantity or appearance of endothelial cells assessed after surgery.¹⁸

Limitations of the study included its observational

nature, potential confounding variables, and the absence of randomization in surgeon hand dominance.

This study just focuses on SIA outcomes however the study with broader focus in terms of visual outcomes, intraoperative and postoperative complications between dominant and non-dominant hand may further help to establish the comparative results.

CONCLUSION

Despite the challenges of adapting surgical technique to accommodate hand dominance, our findings indicate a non-significant difference in postoperative outcomes. The alternative is to shift incision placement to a superior or superonasal position, although this also presents its own set of challenges.

The main change is replacing “it also” with “this also”. While “it also” isn't grammatically incorrect, “this also” flows better in this context, as “this” refers directly to ‘shifting incision placement’. This makes the sentence more concise and direct.

Funding: This study was not funded by any organization.

Patient's Consent: Researchers followed the guidelines set forth in the Declaration of Helsinki.

Conflict of Interest: Authors declared no conflict of interest.

Ethical Approval: The study was approved by the Institutional review board/Ethical review board (ANMC/IBR/00021).

REFERENCES

- Vajpayee RB, Moulick P, Sharma N, Tandon R.** Left-handed non-dominant hand phacoemulsification. *Br J Ophthalmol.* 2003;**87**(5):660. Doi: 10.1136/bjo.87.5.660-a.
- Ernest P, Hill W, Potvin R.** Minimizing surgically induced astigmatism at the time of cataract surgery using a square posterior limbal incision. *J Ophthalmol.* 2011;**2011**:243170. Doi: 10.1155/2011/243170.
- Icoz M, GurturkIcoz SG.** Comparison of dominant and non-dominant-hand cataract surgery outcomes by a single surgeon. *Photo diagnosis Photodyn Ther.* 2024;**45**:103895. Doi: 10.1016/j.pdpdt.2023.103895.
- Anderson M, Carballo E, Hughes D, Behrer C, Reddy RM.** Challenges training left-handed surgeons. *Am J Surg.* 2017;**214**(3):554-557. Doi: 10.1016/j.amjsurg.2016.12.011.
- Mukherjee A, Kalamkar C, Rao R, Patel B.** Technique modifications in manual small-incision cataract surgery for left-handed cataract surgeons. *Indian J Ophthalmol.* 2022;**70**(11):4076-4078. Doi: 10.4103/ijo.IJO_1560_22.
- Gupta SN, Goel R, Kumar S.** Factors affecting surgically induced astigmatism in manual small-incision cataract surgery. *Indian J Ophthalmol.* 2022;**70**(11):3779-3784. Doi: 10.4103/ijo.IJO_1034_22.
- Kageyama T, Yaguchi S, Metori Y, Chida M, Koizumi K, Onishi T, et al.** Visual results and complications of temporal phacoemulsification performed with the non-dominant left hand by junior ophthalmologists. *Br J Ophthalmol.* 2002;**86**(11):1222-1224. Doi: 10.1136/bjo.86.11.1222.
- Barequet IS, Yu E, Vitale S, Cassard S, Azar DT, Stark WJ.** Astigmatism outcomes of horizontal temporal versus nasal clear corneal incision cataract surgery. *J Cataract Refract Surg.* 2004;**30**(2):418-423. Doi: 10.1016/S0886-3350(03)00492-9.
- Vyas VJ, Dubey S, Bhalodia HJ, Pandey A.** Study of comparison of surgically induced astigmatism after small incision cataract surgery and phacoemulsification surgery. *Indian J Clin Exp Ophthalmol.* 2023;**9**(2):226-231. Doi: 10.18231/j.ijceo.2023.043
- Hazra S, Saha TK.** A comparative study of post-operative astigmatism in superior versus superotemporal scleral incisions in manual small incision cataract surgery in a tertiary care hospital. *Int J Clin Exp Ophthalmol.* 2021;**5**:9–15. Doi: 10.29328/journal.ijceo.1001036
- Reddy B, Raj A, Singh VP.** Site of incision and corneal astigmatism in conventional SICS versus phacoemulsification. *Ann Ophthalmol (Skokie).* 2007;**39**(3):209–216. Doi: 10.1007/s12009-007-0020-y
- George R, Rupauliha P, Sripriya AV, Rajesh PS, Vishnu P, Vahan, et al.** Comparison of endothelial cell loss and surgically induced astigmatism following conventional extracapsular cataract surgery, manual small incision surgery and phacoemulsification. *Ophthalmic Epidemiol.* 2005;**12**(5):293–297. Doi: 10.1080/09286580591005778
- Nikose AS, Saha D, Laddha PM, Patil M.** Surgically induced astigmatism after phacoemulsification by temporal clear corneal and superior clear corneal approach: a comparison. *Clin Ophthalmol.* 2018;**12**:65-70. Doi: 10.2147/OPHTH.S149709

13. **Chung AT, Lenci LT, Wang K, Collins TE, Griess MD, Oetting TA, et al.** Effect of fine-motor-skill activities on surgical simulator performance. *J Cataract Refract Surg.* 2017;**43(7)**:915-922. Doi: 10.1016/j.jcrs.2017.05.024
14. **Gonzalez-Gonzalez LA, Payal AR, Gonzalez-Monroy JE, Daly MK.** Ophthalmic surgical simulation in training dexterity in dominant and non-dominant hands: results from a pilot study. *J Surg Educ.* 2016;**73(4)**:699-708. Doi: 10.1016/j.jsurg.2016.01.014
15. **Park J, Williams O, Waqar S, Modi N, Kersey T, Sleep T.** Safety of non-dominant-hand ophthalmic surgery. *J Cataract Refract Surg.* 2012;**38(12)**:2112-2116. Doi: 10.1016/j.jcrs.2012.07.030
16. **Sharma V, Sinha R, Sharma N, Dada T, Tandon R, Titiyal JS, et al.** Phacoemulsification with non-dominant hand. *Eye.* 2007;**21(8)**:1037-1040. Doi: 10.1038/sj.eye.6702390
17. **İçöz M, İçöz ŞG, Yorgun MA.** Effect of non-dominant left-handed phacoemulsification surgery on corneal endothelium. *Cureus.* 2023;**15(3)**. Doi: 10.7759/cureus.36744

Authors Designation and Contribution

Zia-ul-Mazhry; *Head of Department: Concepts, Design, Literature search, Manuscript preparation, Manuscript editing, Manuscript review.*

Laiba Asif; *Medical Officer: Literature search, Manuscript preparation, Manuscript editing, Manuscript review.*

Muhammad Abdullah Mazhry; *Medical Officer: Manuscript preparation, Manuscript editing, Manuscript review.*

Faiza Hassan; *Optometrist: Literature search, Manuscript preparation, Manuscript review.*

Muhammad Saeed; *Professor: Design, Manuscript review.*

