

# Cases of Subconjunctival Hemorrhage After a Joy Ride

Roomasa Channa, Sana Shoukat Memon, Tanveer A. Chaudhry, Khabir Ahmad

*Pak J Ophthalmol 2008, Vol. 24 No. 1*

.....  
See end of article for  
authors affiliations

.....  
Correspondence to:  
Tanveer Anjum Chaudhry  
Section of Ophthalmology  
Department of Surgery  
Aga Khan University, Karachi

Received for publication  
May' 2007  
.....

**S**ubconjunctival hemorrhage is a benign condition that mostly resolves spontaneously on its own, even though it may be very alarming for the patients. Multiple causes of subconjunctival hemorrhage-including local trauma, acute conjunctivitis and systemic hypertension have been reported in literature<sup>1, 2</sup>.

## CASES

We report here a series of four cases of subconjunctival hemorrhage that occurred following a gyroscopic ride. During Easter break, a group of 4 college students, two boys and two girls, between the ages of 17-19 years, presented to the outpatient department of Barnsley District General Hospital with red eyes. Couple of hours before presenting at the eye clinic, they reported going on a gyroscopic ride outside a local pub. After the ride, they noticed red patches in white of their eyes (Table 1, Fig. 1).

They did not have any history of co-morbid, such as hypertension, diabetes, blood dyscrasias or clotting abnormalities. They were also not using any blood thinning medications, like Aspirin or Warfarin. General examination showed that vitals including blood pressures were within normal ranges.

Their visual acuity was normal. All four, but one patient had bilateral subconjunctival hemorrhages on

the lateral or medial or both sides of the limbus (Fig. 1). IOP was normal and there was no reaction in the anterior chamber. Their pupils were reacting normally and detailed retinal examination did not reveal any pathology such as retinal edema, hemorrhage or tear. Laboratory investigations revealed normal bleeding and clotting profiles.

Patients were not given any medication, reassured and sent home. Three of them returned for examination two weeks later. All hemorrhages had completely resolved.

## DISCUSSION

Eye hemorrhages and retinal tears caused by amusement rides and high intensity sports such as bungee jumping and roller coaster rides have been reported previously. During 1987-2000 one person in the United States had retinal tear and a possible cerebral edema and five others had eye hemorrhage after they rode a hand-powered ride called the "Spaceball" which spins its occupants at a high speed. In addition, a boy aged 17 had vitreous hemorrhage after a gyroscopic ride<sup>3, 4</sup>. Our case series is unique in that all four members of the group developed subconjunctival hemorrhage following a gyroscopic ride. To the best of our knowledge this is the first reported case series of subconjunctival hemorrhages

associated with this type of ride. There is a possibility that many such cases of subconjunctival hemorrhage are not reported because they are not sight threatening.

A gyroscope is a device consisting of a rotating heavy metal wheel pivoted inside a circular frame (Fig 2). The wheel's rotation enables it to retain its original orientation in space when the frame turns. The ride works on exactly the same principle and the high speed rotation of the passenger in multiple directions can cause rupture of the thin conjunctival vessels.

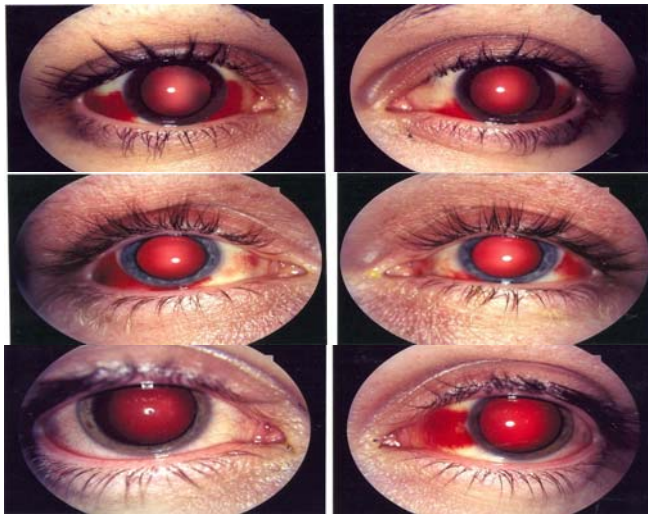


Fig. 1: Location of subconjunctival hemorrhages in three of four cases

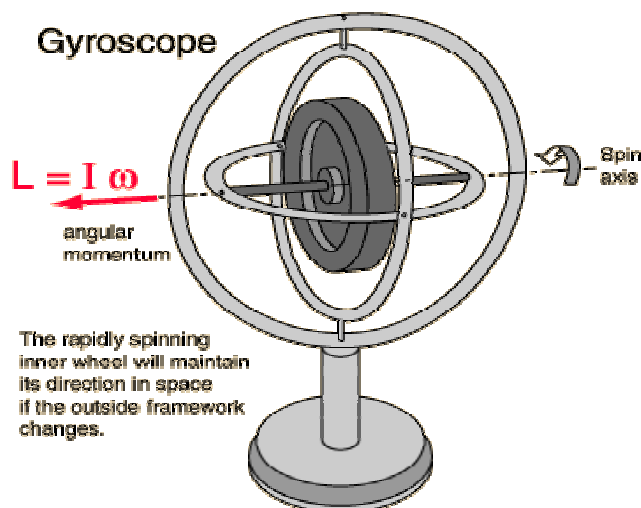


Fig. 2: A gyroscope: its structure and function

## CONCLUSION

Although extreme sports are very attractive, mostly for the younger generation, they can result in eye trauma ranging from benign hemorrhage to a sight-threatening retinal damage. One should observe caution while thinking of indulging in such sports and seek medical advice immediately if there is any associated eye trauma.

## Author's affiliation

Dr. Roomasa Channa  
 Section of Ophthalmology, Department of Surgery,  
 Aga Khan University  
 P O BOX 3500, Stadium Road  
 Karachi

Dr. Sana Shoukat Memon  
 Section of Ophthalmology, Department of Surgery,  
 Aga Khan University  
 P O BOX 3500, Stadium Road  
 Karachi

Dr. Tanveer A. Chaudhry  
 Section of Ophthalmology, Department of Surgery,  
 Aga Khan University  
 P O BOX 3500, Stadium Road  
 Karachi

Dr. Khabir Ahmad  
 Section of Ophthalmology, Department of Surgery,  
 Aga Khan University  
 P O BOX 3500, Stadium Road  
 Karachi

## REFERENCE

1. **Leibowitz HM.** The red eye. *N Engl J Med.* 2000; 343: 345-51.
2. **Fukuyama J, Hayasaka S, Yamada K, et al.** Causes of subconjunctival hemorrhage. *Ophthalmologica.* 1990; 200: 63-7.
3. **Jain BK, Talbot EM.** Bungee jumping and intraocular haemorrhage. *Br J Ophthalmol.* 1994; 78: 236-7.
4. **Morris CC.** Amusement Ride-Related Injuries and Deaths in the United States: 1987-2000. In: Bethesda, MD: US Consumer Product Safety Commission; 2001.