

Efficacy of Intralesional Triamcinolone Acetonide for the Treatment of Chalazion

Tanweer Hassan Khan, Shakir Zafar, Waqar-ul-Huda

Pak J Ophthalmol 2017, Vol. 33 No. 1

See end of article for authors affiliations

Correspondence to:
Waqar-ul-Huda
Associate ophthalmologist,
LRBT free tertiary eye care
hospital korangi, Karachi
Email: waqarhuda@yahoo.com

Purpose: To assess the Resolution of Chalazion after intralesional injection of Triamcinolone Acetonide at tertiary care hospital in Karachi.

Study Design: Case series.

Place and Duration of study: LRBT free tertiary eye care hospital Karachi from January 2016 to June 2016.

Material and Methods: A case series was done in 62 eyes of 62 patients using intralesional injection of triamcinolone acetonide in patients of chalazion. The patients included in the case series were those who had chalazion and presented to outpatient department from January 2016 to June 2016. The patients were included using non-probability purposive sampling technique. The size of the chalazion was measured by using measurement rings of different sizes. Resolution of chalazion after intralesional injection of triamcinolone acetonide at 2 weeks was noted. Data analysis was done using SPSS version 13.0.

Results: Fifty (80.6%) patients showed complete resolution of the lesion with single injection of triamcinolone acetonide. Complete resolution of chalazion after treatment was directly associated with the duration of chalazion. With longer duration of the lesion complete resolution of the lesion decreased.

Conclusion: Intralesional triamcinolone acetonide injection is very useful in resolving chalazion of different sizes, so this treatment can be used as a convenient treatment option for chalazion.

Keywords: Chalazion, Intralesional, Triamcinolone acetonide

A chalazion is a lipogranulomatous lesion of the eyelid that develops due to the retention of meibomian gland secretion. The granuloma contains various inflammatory cells, including epithelioid and giant cells, neutrophils, eosinophils, and lymphocytes. The condition affects people of all ages and is one of the common eye diseases.

Approximately 25% of chalazion resolves by itself¹. The use of warm compresses and hygiene of the lids², intralesional steroid injection^{3,4}, and incision and curettage are the different treatment options. Treatment with warm compresses and lid hygiene are based on patient compliance, while incision and

curettage is a relatively painful procedure and needs local anesthesia or general anesthesia especially in children.

Intralesional corticosteroid therapy of chalazion is not a new procedure⁵. Intralesional triamcinolone acetonide injection of chalazion is an effective, easy and a safe method⁶.

This study will give an effective alternative option for chalazion in patients like children, patients with allergy to local anaesthetics and in those who have fear for operation theatre environment and surgery. It is particularly suitable for chalazion located close to the lacrimal punctum.

Material and Methods:

A case series including 62 patients was done using intralesional injection of triamcinolone acetonide in patients of chalazion. The patients included in the case series were those who had chalazion and presented to outpatient department from January 2016 to June 2016. The patients were categorized with respect to the duration of the lesion into 3 categories i.e. less than 2 months, between 2 and 3 months and more than 3 months. The patients were also categorized with respect to size of the lesion into 2 groups. i.e. less than 5 mm and 5 or more. Sizing of the lesion was done using measurement rings of different sizes. The patients included in the study were having chalazion diagnosed clinically on either upper or lower eyelid with slit lamp biomicroscope, 15 years of age so that the injection could be easily injected intralesionally under topical anesthesia and of either gender. The patients excluded from the study were those having infected chalazion, previously medically or surgically treated lesions, patients with any associated predisposing ocular or systemic co-morbidity.

The patients were included using non-probability purposive sampling technique. Informed written consent was taken after explaining the purpose and procedure of the study. The size of the chalazion was measured by using measurement rings of different sizes. The conjunctiva was first anaesthetized with proparacaine HCL eye drops. Triamcinolone acetonide 0.1 ml diluted with lignocaine to a concentration of 5mg/ml was injected through the conjunctiva into the lesion with the 30-gauge needle⁷. On examination, if there was no palpable mass on the eyelid, it was considered as complete resolution of chalazion after 2 weeks. These findings were entered into the proforma. Data analysis was done using SPSS version 13.0.

RESULTS

Most of the patients were between 31 to 50 years of age that is 60.2% as shown in figure 1a. The average age of the patients was 38.7 ± 14.2 years. Out of 62 patients, 27 (44%) were male and 35 (56%) were female. Similarly average duration of chalazion and size of chalazion were 2.8 ± 1.8 months and 4.5 ± 3.0 mm respectively as presented in table 1.

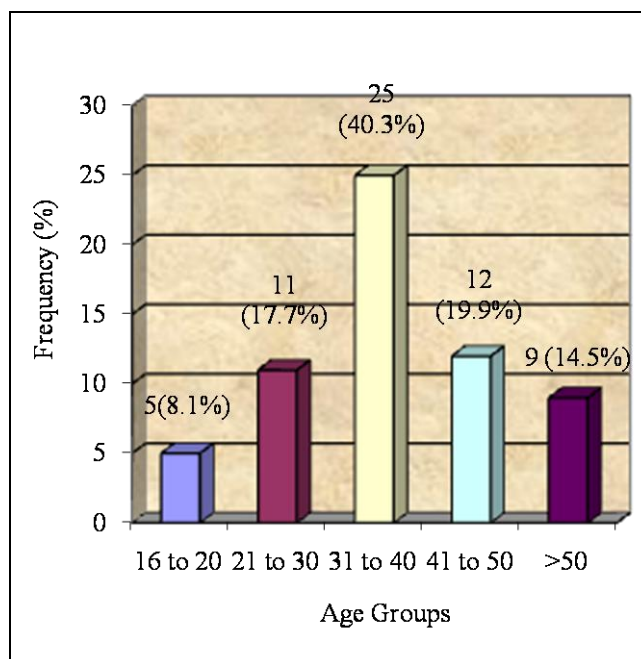


Fig. 1a: Age Distribution of the Patients.

Table 1:

Variables	Mean \pm SD	95% CI
Age (Years)	38.7 ± 14.2	37.5 to 42.3
Duration of Chalazion (months)	2.8 ± 1.8	2.3 to 4.2
Size of Chalazion (mm)	4.5 ± 3.1	4.12 to 5.82

Duration of chalazion was 2 to 3 months in 35 (57%) patients, above 3 months in 15 (24%) and below 2 months in 12 (19%) patients as shown in figure 1b. Similarly size of chalazion was less than and equal to 5 mm in 40 (65%) cases while greater than 5 mm were observed in 22 (35%) cases as shown in figure 2. Results of resolution of chalazion after intralesional injection of triamcinolone acetonide at 2 weeks is presented in figure 3. Fifty (80.6%) patients experienced complete resolution of the lesion with treatment of single injection while remaining 12 patients exhibited no response to the treatment.

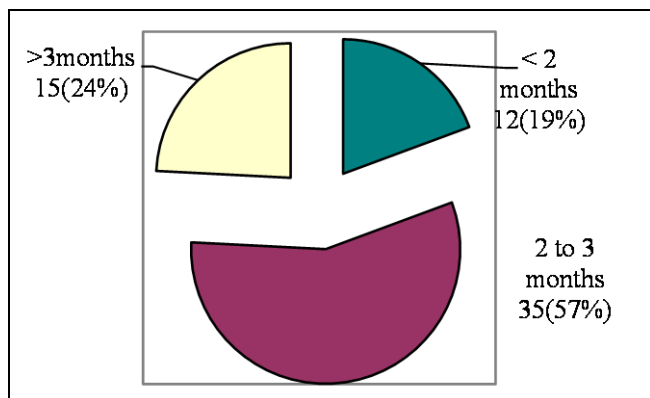


Fig. 1b: Duration of chalazion.

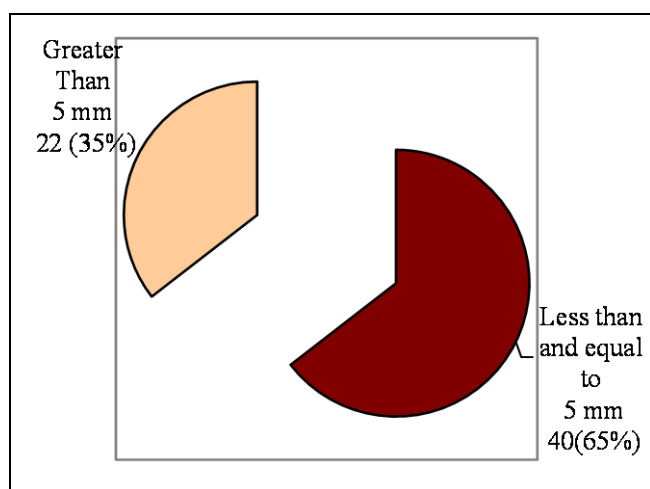


Fig. 2: Size of chalazion.

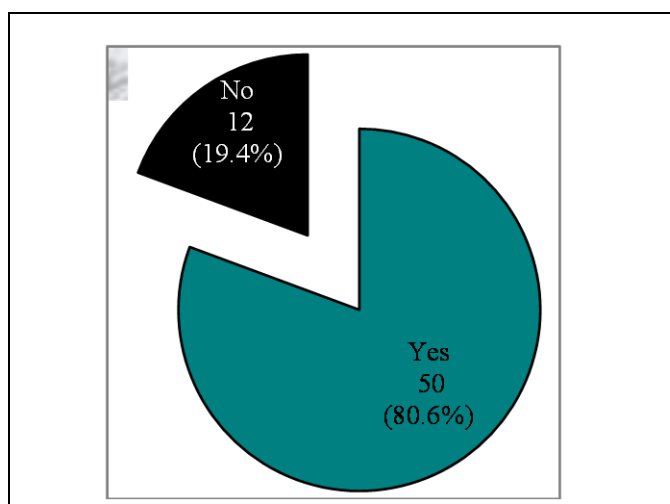


Fig. 3: Resolution of chalazion after intralesional injection of triamcinolone acetonide at 2 weeks.

Data was also analyzed with respect to age groups, size and duration of chalazion as presented in table 2 to 4. Complete resolution of chalazion was high that is 72.7% to 96% in all age groups whereas it was low in above 50 years of age (44.4%) as shown in table 2.

Table 2: Resolution of chalazion after intralesional injection of triamcinolone acetonide with respect to age groups.

Age Groups	n	Resolution of Chalazion	
		Yes n = 50	No n = 12
16 to 20 Years	5	4 (80%)	1 (20%)
21 to 30 Years	11	8 (72.7%)	3 (27.3%)
31 to 40 Years	25	24 (96%)	1 (4%)
41 to 50 Years	12	10 (83.3%)	2 (16.7%)
> 50 Years	9	4 (44.4%)	5 (55.6%)

Complete resolution was 100% in those patients whose duration of chalazion was below 2 months and 85.7% in those patients whose duration were between 2 to 3 months while it was observed low (53.3%) in those patients who tolerated above 3 months as shown in table 3.

Table 3: Resolution of chalazion after intralesional injection of triamcinolone acetonide with respect to duration of chalazion.

Duration of Chalazion	N	Resolution of Chalazion	
		Yes n = 50	No n = 12
< 2 months	12	12(100%)	0 (0%)
2 to 3 months	35	30 (85.7%)	5 (14.3%)
> 3 months	15	8 (53.3%)	7 (46.7%)

Complete resolution of chalazion was high in those patients whose size of chalazion was less than and equal to 5 mm as shown in table 4.

DISCUSSION

Chalazion is one of the most common eyelid lesions presenting in the outpatient department in daily

routine clinics. It normally presents as a firm nodular, painless swelling extending either anteriorly toward the skin or posteriorly toward the conjunctiva⁸.

Table 4: Resolution of chalazion after intralesional injection of triamcinolone acetonide with respect to size of chalazion.

Size of Chalazion (mm)	n	Resolution of Chalazion	
		Yes n=50	No n=12
≤ 5 mm	40	38 (95%)	2 (5%)
> 5 mm	22	12 (54.5%)	10 (45.5%)

In a study⁹, it was shown that more than 25% chalazion resolve by itself, but the others are dubious to resolve without any treatment. The usual standard management of these lesions is by incision and curettage, which is often a minor surgical procedure but causes discomfort and distress to the patient.

There is a study¹⁰, in which they have compared the three methods of treatment of chalazion, intralesional triamcinolone acetonide injection, incision and curettage and the combination of incision, curettage and intralesional triamcinolone acetonide injection. The results demonstrated that the intralesional triamcinolone acetonide injection was a rapid and most effective method of treatment¹⁰. This is consistent with the results of our study.

Several studies have showed the result of intralesional or subcutaneous steroid injection for the treatment of chronic chalazion with reported success and resolution in up to 95% of the cases. In our study we have found resolution of chalazion from 73% to 96%.

There is a study done by Ben Simon GI¹¹, evaluated the safety and efficiency of intralesional triamcinolone acetonide (TA) injection in chalazion. They showed that, intralesional injection of TA in primary and recurrent chalazia is effective in achieving lesion regression. This is again consistent with our study results.

In a similar study¹², Kaimbo assessed the efficacy of intralesional corticosteroid injection in the management of chalazia and brought to a conclusion that intralesional corticosteroid injection appears to be effective in managing chalazion¹². Khanna¹³ also showed similar results in one study.

Intra-lesional corticosteroid treatment for the same is still simple, economical and a convenient procedure without any major complication^{14,15}. The intralesional corticosteroid injection was considered to be the most reasonable one due to several reasons. There is no need for eye padding, less painful, more economical, does not require much skill, does not need local anesthesia and can be performed in children. Dexamethasone, a water soluble drug has been tried in few studies but the results were not encouraging¹⁶.

There is an important study done in Pakistan¹⁷, in which they have compared the outcome of intralesional corticosteroid injection and surgical treatment of chalazia. 79% of patients in surgical treatment group and 62% of patients in steroid injection group at first visit after two weeks showed success in chalazion resolution. The success in surgical treatment group improved to 89% of patients after second operation and to 80% of patients in steroid injection group after second injection of the steroid given at second week¹⁷. These results are also comparable with the results of our study.

In the absence of a control group in the current study, it is important to highlight that our guidelines merely represent our clinical experience, and the efficacy of triamcinolone acetonide injection versus natural remission cannot be evaluated. Our finding is in line with earlier studies in which steroid injection resulted in a 50% to 95% success rate and in clinical remission of the chalazion^{18,19}. Our study was in contrast to Prasad and Gupta²⁰ who compare subconjunctival total removal with incision, curettage, and intralesional steroid injection. Several issues make surgery a less desirable option for many patients, especially in the younger age group; for instance, patients may have psychological fear of surgery as opposed to medical treatment or an injection²¹. Certainly, as a recent survey by a Canadian group²² suggests chalazion surgery should be treated with the same respect as any other operation. There have been very rare reported complications such as retinal and Choroidal vascular occlusion²³ and inadvertent globe penetration, skin depigmentation at the site of injection and delayed post-injection hemorrhage in an elderly hypertensive patient^{24,25}. Depigmentation changes are described in a minority of patients¹⁹. In general, our patients were satisfied with the Triamcinolone Acetonide injection and in most cases, they preferred repeated injections to surgery.

CONCLUSION

Intralesional triamcinolone acetonide injection is very useful in resolving chalazion of different sizes, although it is almost 100% effective when the chalazion size is smaller and of lesser duration. This treatment can be used in future as a convenient treatment option especially for small sized chalazion.

Author's Affiliation

Dr. Tanweer Hassan Khan
Associate Ophthalmologist, LRBT free tertiary eye care hospital korangi Karachi.

Dr. Shakir Zafar
Consultant Ophthalmologist, LRBT free tertiary eye care hospital korangi, Karachi.

Dr. Waqar-ul-Huda
Associate ophthalmologist, LRBT free tertiary eye care hospital korangi, Karachi.

Role of Authors

Dr. Tanweer Hassan Khan
Formulating the protocol, Data analysis, writing of manuscript.

Dr. Shakir Zafar
Manuscript review.

Dr. Waqar-ul-Huda
Formulating the protocol, Data analysis, writing of manuscript.

REFERENCES

1. **Cottrell D, Bosanquet R, Fawcett I.** Chalazions: the frequency of spontaneous resolution. *BMJ.* 1983; 287 (6405): 1595-1595.
2. **Perry H, Serniuk R.** Conservative treatment of chalazia. *Ophthalmology* 1980; 87 (3): 218-221.
3. **Pizzarello L, Jakobiec F, Hofeldt A, Podolsky M, Silvers D.** Intralesional corticosteroid therapy of chalazia. *American Journal of Ophthalmology.* 1978; 85 (6): 818-821.
4. **Singh Dua H, Nilawar D.** Nonsurgical therapy of chalazion. *American Journal of Ophthalmology.* 1982; 94 (3): 424-425.
5. **Leinfelder P.** Depo-Medrol in treatment of acute chalazion. *American Journal of Ophthalmology.* 1964; 58 (6): 1078.
6. **Ahmad S, Baig M, Khan M, Khan I, Janjua T.** Intralesional corticosteroid injection vs. surgical treatment of Chalazia in pigmented patients, *J Coll Physicians Surg Pak.* 2006; 16 (1): 42-44.
7. **Colon M, Sutula F.** Congenital eyelid abnormalities. In: Albert DM, Jakobiec FA, Eds. *Principles and practice of ophthalmology.* Philadelphia: WB Saunders Company, 1995: 1693.
8. **Cottrell D, Bosanquet R, Fawcett I.** Chalazions: the frequency of spontaneous resolution. *BMJ.* 1983; 287 (6405): 1595-1595.
9. **Cottrell D, Bosanquet R, Fawcett I.** Chalazions: the frequency of spontaneous resolution. *BMJ.* 1983; 287 (6405): 1595-1595.
10. **Thabit A. M, Ismat H. O.** Three methods of treatment of Chalazia in children. *Saudi medical journal.* 2001; 22 (11): 968-972.
11. **Bensimon G, Huang L, Nakra T, Schwarcz R, McCann J, Goldberg R.** Intralesional triamcinolone acetonide injection for primary and recurrent chalazia: is it really effective? *Ophthalmology.* 2005; 112 (5): 913-917.
12. **Kaimbo W.** Intralesional corticosteroid injection in the treatment of chalazion. *Journal français d'ophtalmologie.* 2004; 27 (2): 149-153.
13. **Khanna K, Mittal O.** Non-surgical treatment of chalazion. *Indian journal of ophthalmology.* 1981; 29 (2): 83-85.
14. **Castress J, Stressborg T.** Corticosteroid injection of Chalazia *Acta Ophthalmologica.* 2009; 61 (5): 938-942.
15. **Pizzarello L, Jakobiec F, Hofeldt A, Podolsky M, Silvers D.** Intralesional corticosteroid therapy of chalazia. *American Journal of Ophthalmology.* 1978; 85 (6): 818-821.
16. **Panda A, Angra S.** Intralesional corticosteroid therapy of chalazia. *Indian journal of ophthalmology.* 1987; 35 (4): 183-185.
17. **Ahmad S, Baig M, Khan M, Khan I, Janjua T.** Intralesional corticosteroid injection vs. surgical treatment of Chalazia in pigmented patients. *J Coll Physicians Surg Pak.* 2006; 16 (1): 42-44.
18. **Khurana A, Ahluwalia B, Rajan C.** Chalazion therapy. Intralesional steroids versus incision and curettage. *Acta Ophthalmol.* 1988; 66: 352- 354.
19. **Mohan K, Dhir S, Munjal V, Jain I.** The use of intralesional steroids in the treatment of chalazion. *Ann Ophthalmol.* 1986; 18: 158-160.
20. **Prasad S, Gupta A.** Subconjunctival total excision in the treatment of chronic chalazia. *Indian J Ophthalmol* 1992; 40 (4): 103-105.
21. **Li R, Lai J, Ng J, et al.** Efficacy of lignocaine 2% gel in chalazion surgery. *Br J Ophthalmol* 2003; 87 (2): 157-159.
22. **Smythe D, Hurwitz JJ, Tayfour F.** The management of chalazion: a survey of Ontario ophthalmologists. *Can J Ophthalmol.* 1990; 25: 252-5.
23. **Thomas EL, Laborde RP.** Retinal and choroidal vascular occlusion following intralesional corticosteroid injection of a chalazion. *Ophthalmology* 1986; 93: 405-7.
24. **Hosal BM, Zilelioglu G.** Ocular complication of intralesional corticosteroid injection of a chalazion. *Eur J Ophthalmol* 2003; 13: 798-9.
25. **Procope JA, Kidwell ED Jr.** Delayed postoperative hemorrhage complicating chalazion surgery. *J Natl Med Assoc.* 1994; 86: 865-6.